

Caso Clínico

Síndrome de Marine-Lenhart: Um Caso Raro de Hipertiroidismo



Joana Maurício^{a,*}, Marta Arriaga Rocha^a, Susana Heitor^a

^aServiço de Medicina III - Hospital Prof. Doutor Fernando Fonseca, Amadora, Portugal.

INFORMAÇÃO SOBRE O ARTIGO

Historial do artigo:

Received/ Recebido: 2020-02-03

Accepted/Aceite: 2020-03-15

Online: 2020-07-08

© Autor (es) (ou seu (s) empregador (es)) 2020.

Reutilização permitida de acordo com CC BY-NC. Nenhuma reutilização comercial.

© Author(s) (or their employer(s)) 2020.

Re-use permitted under CC BY-NC.

No commercial re-use.

Palavras-chave:

Doença de Graves;

Hipertiroidismo;

Nódulo da Tiróide;

Síndrome.

Keywords:

Graves Disease;

Hyperthyroidism;

Syndrome;

Thyroid Nodule.

R E S U M O

A síndrome de Marine-Lenhart é uma causa rara de hipertiroidismo, caracterizada pela coexistência da doença de Graves e um nódulo funcionante ou bócio multinodular tóxico. Mulher de 88 anos com queixas de dispneia, edema dos membros inferiores, diarreia, disфонia e intolerância ao calor. Ao exame físico com bócio multinodular. Analiticamente com NT-proBNP elevado, TSH suprimida, T4 e T3 livre elevadas e anticorpos anti-receptor TSH positivos. Eletrocardiograma com fibrilhação auricular inaugural. Assumido o diagnóstico de insuficiência cardíaca aguda em contexto de fibrilhação auricular de novo e hipertiroidismo, tendo sido iniciada terapêutica. Ecografia com glândula tiroideia multinodular e cintigrafia com tecnésio-99m (Tc-99m) com a presença de nódulos hiper e hipofuncionantes, sugerindo o diagnóstico de síndrome de Marine-Lenhart. Embora a autoimunidade positiva e o padrão ecográfico confirmem a etiologia da maioria dos casos de doença de Graves, a cintigrafia pode ser útil em casos de bócio multinodular, pois altera a abordagem terapêutica.

Marine-Lenhart Syndrome: A Rare Cause of Hyperthyroidism

A B S T R A C T

Marine-Lenhart syndrome is a rare cause of hyperthyroidism, characterized by the coexistence of Graves' disease and a functioning nodule or toxic multinodular goiter. An 88-year-old female was admitted to the emergency department with dyspnea, lower limbs' edema, diarrhea, dysphonia and heat intolerance. During physical examination a multinodular goiter was identified. Blood tests showed elevated NT-proBNP, suppressed TSH, elevated free T4 and free T3 and positive TSH receptor antibodies. Electrocardiogram revealed new-onset atrial fibrillation. Diagnosis of acute heart failure in a patient with de novo atrial fibrillation and hyperthyroidism was assumed and specific treatment was initiated. Thyroid ultrasound showed a multinodular enlarged gland and technetium-99m (Tc-99m) scintigraphy showed hyper and hypofunctioning nodules, suggesting the diagnosis of Marine-Lenhart syndrome. Although autoimmune tests and thyroid ultrasound pattern confirm the etiology of most of Graves' diseases, scintigraphy may be useful in multinodular goiter cases, because it changes the therapeutic approach.

* Autor Correspondente / Corresponding Author.

E-Mail: joana.mauricio@hff.min-saude.pt (Joana Maurício)

Serviço de Medicina III - Hospital Prof. Doutor Fernando Fonseca, IC 19 2720-276, Amadora, Portugal

Introduction

Unlike hypothyroidism, which becomes more prevalent with age, the incidence of Graves' disease peaks between 30 and 50 years of age, although people can be affected at any age.¹ Thyroid nodules are also very common, being palpable in approximately 5% in women and 1% in men, and detectable on ultrasound in 19%-68% in the general population.² The prevalence of thyroid nodules has been shown to be higher in women and the elderly, and most of these nodules are non-functioning and cause no symptoms.^{2,3}

Marine-Lenhart syndrome, described in 1911, is a condition characterized by the coexistence of Graves disease and a functioning nodule or toxic multinodular goiter. This is a rare and controversial cause of hyperthyroidism, with a reported prevalence of 0.8%-2.7% in patients with Graves disease.⁴

We present a case of Marine-Lenhart syndrome in an octogenarian female.

Case Report

An 88-year-old female, previously healthy, with no medical history, no previous surgeries or hospitalizations, no usual medication or known allergies, was admitted to the emergency department with shortness of breath, exertional dyspnea, nonproductive cough, and edema of the lower limbs, with one-week duration. She also complained of diarrhea, dysphonia and heat intolerance with six weeks duration, with no fever, weight loss, headache, visual or sleep pattern changes.

At physical examination her blood pressure was normal (139/60 mmHg), but her heart rate was elevated (118 bpm). Cardiac sounds were arrhythmic, and she presented with bibasilar crackles at lung auscultation and symmetrical lower limbs' edema. She also had a slightly enlarged thyroid gland, with ill-defined borders, and no signs or symptoms of orbitopathy. Laboratory tests revealed an elevated NT-proBNP at 2932 pg/mL (normal range: <738 pg/mL), TSH below 0.005 mUI/mL (normal range: 0.270-4.200 mUI/L), an elevated free T4 at 3.34 ng/dL (normal range: 0.93 – 1.70 ng/dL) and an elevated free T3 at 14.3 pg/mL (normal range: 2.00 – 4.40 pg/mL), with no history of previous exposure to iodinated contrast or other products containing iodine. The TSH receptor antibodies (TRAb) were positive at 27.8 UI/L (normal range: <1.75 UI/L). The electrocardiogram revealed new-onset atrial fibrillation with a heart rate of 122 bpm and chest radiography revealed interstitial edema. It was assumed the diagnosis of acute heart failure, in a patient with de novo AF, in the context of hyperthyroidism. Diuretic (furosemide), beta-blocker (bisoprolol) and anticoagulation (subcutaneous enoxaparin) were started, as well as therapy with methimazole, at the dose of 15 mg a day.

Thyroid ultrasound described an enlarged (left lobe 20 x 24 x 61 mm and right lobe 23 x 21 x 58 mm), diffusely heterogeneous and multinodular thyroid gland, with a substernal goiter component, of which stood out: in the right lobe, a 24 mm mixed predominantly solid isoechoic nodule with regular contours, an 11 mm hyperechoic solid nodule with regular contours, a 12 mm mixed predominantly solid and hyperechoic nodule with regular contours; and in the left lobe, a 33 mm mixed predominantly solid and isocogenic nodule, with regular contours (Fig. 1). There were also multiple solid infra-centimeter hyperechoic nodules in the left lobe, all of them with regular contours.

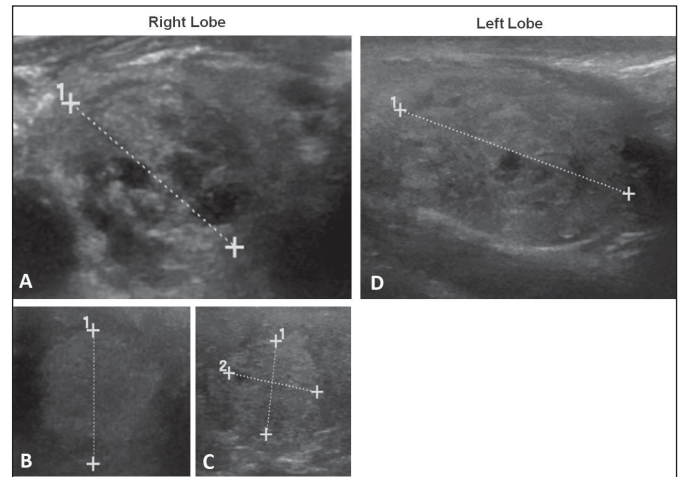


Figure 1. Thyroid ultrasound. Right Lobe: (A) 24 mm mixed predominantly solid isoechoic nodule; (B) and (C) 12 mm and 11 mm hyperechoic solid nodules. Left Lobe: (D) 33 mm mixed predominantly solid isoechoic nodule.

One month later, and after stopping methimazole in the previous 7 days, scintigraphy with Tc-99m was performed. Thyroid gland demonstrated increased uptake of Tc-99m at 6.8% (normal range: 1%-3.5%), with a multinodular goiter with hyperfunctioning nodules (middle third of the right lobe and upper third of the left lobe) and hypofunctioning nodules (lower and upper third of the right lobe and lower two thirds of the left lobe) (Fig. 2). The diagnosis was consistent with Marine-Lenhart syndrome.

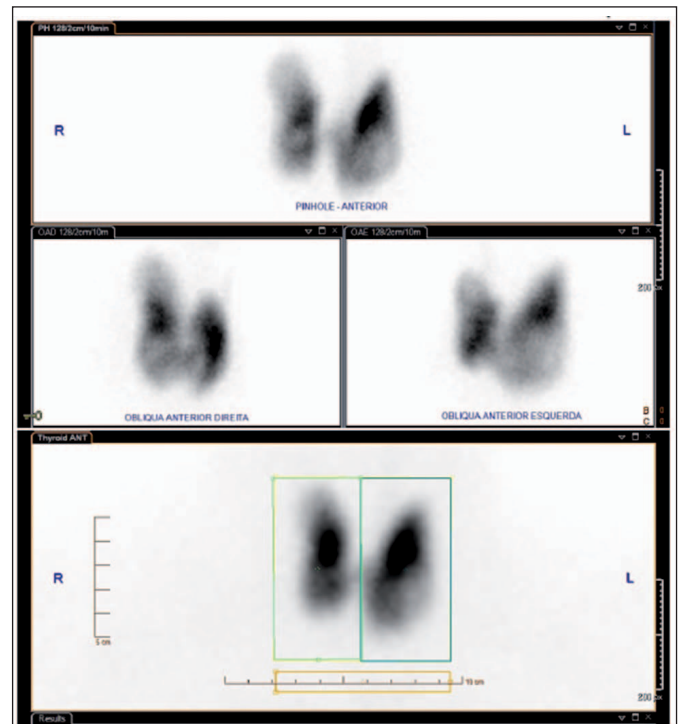


Figure 2. Thyroid scintigraphy with Tc-99m. Multinodular goiter, with hyperfunctioning ("hot") nodules and hypofunctioning ("cold") nodules in both lobes.

Although the patient had a formal indication for cold nodule cytology and definitive treatment, due to age, comorbidities and low-risk malignancy thyroid nodules, it was decided to maintain a conservative therapy and surveillance. Over the next months, the

patient maintained 5 mg a day of methimazole, with normalized free T4, free T3 and TSH values, and no symptoms.

Discussion

Thyroid nodules, which occur in 10%-15% of patients with Graves' disease, may present as pseudo-nodules, nodular goiter, hyperplastic nodules, differentiated thyroid cancer, or as functioning thyroid nodules.⁵ Although the coexistence of Graves' disease and functioning nodules is commonly named Marine-Lenhart syndrome, the diagnosis criteria are still not well established. In order to settle the discrepancies in the definition of the Marine-Lenhart syndrome, Neuman *et al* (2018) proposed the following criteria for the diagnosis and classification of patients with Graves' disease and functioning nodules: 1) thyroid function tests consistent with hyperthyroidism with serological testing for Graves' disease (TRAb); 2) increased radioactive iodine uptake and the presence of "cold" or "hot" nodules; 3) thyroid nodule biopsy revealing a hyperplastic lesion or follicular adenoma.⁴

Although autoimmune testing and thyroid ultrasound pattern confirm the etiology of the majority cases of Graves' disease, thyroid scintigraphy may be useful in selected cases of coexistence of Graves' disease and multinodular goiter, because it can help distinguish hypofunctioning from hyperfunctioning nodules.⁶ In Graves' disease, more than 95% of nodules on thyroid scan are hypoactive, with a small percentage hyperactive nodules, and therefore patients with Marine-Lenhart syndrome can have hyperthyroidism due to both Graves disease and toxic nodular goiter.⁷

Although the few articles that address this syndrome perform mainly iodine scintigraphy for diagnosis, in our clinical case it was only performed scintigraphy with Tc-99m. In these situations nodules may be discordant, that is, hypoactive in Tc-99m scintigraphy but hyperactive in iodine, and this could be pointed as a limitation of our clinical case.

The diagnosis of Marine-Lenhart syndrome is very important because it changes the therapy approach. The therapeutic options include anti-thyroid drugs (ATD), radioactive iodine (RAI) or surgery. Therapeutic strategy should be individualized according to clinical characteristics, age and preference of the patient, attending the advantages and disadvantages of each type of treatment, as well as the experience of the medical team.³ ATD, preferably methimazole, are the first-line therapeutic option for patients with hyperthyroidism. RAI treatment is often recommended for patients with side-effects to or recurrence after a course of ATD. RAI is not contraindicated in large goiters and can also be a good option in patients with compressive symptoms.⁸ Lastly, surgery (preferably total thyroidectomy) is the procedure of choice in cases where malignancy is suspected, when there is moderate to severe ophthalmopathy, in large size or symptomatic compressing goiter, and according to patient preference.³

In our clinical case, the decision of maintaining long term low-dose ATD, to the detriment of RAI treatment and/or surgery, was based on patient preference, advanced age, low risk of malignant nodules and severe kyphoscoliosis that would make it very difficult to perform fine-needle aspiration and/or surgery. With this

approach, in the following evaluations, there was total normalization of free T4, free T3, and TSH values, and the patient was completely asymptomatic.

Responsabilidades Éticas

Conflitos de Interesse: Os autores declaram a inexistência de conflitos de interesse na realização do presente trabalho.

Fontes de Financiamento: Não existiram fontes externas de financiamento para a realização deste artigo.

Confidencialidade dos Dados: Os autores declaram ter seguido os protocolos da sua instituição acerca da publicação dos dados de doentes.

Consentimento: Consentimento do doente para publicação obtido.

Proveniência e Revisão por Pares: Não comissionado; revisão externa por pares.

Ethical Disclosures

Conflicts of Interest: The authors have no conflicts of interest to declare.

Financing Support: This work has not received any contribution, grant or scholarship.

Confidentiality of Data: The authors declare that they have followed the protocols of their work center on the publication of data from patients.

Patient Consent: Consent for publication was obtained.

Provenance and Peer Review: Not commissioned; externally peer reviewed.

References / Referências

1. Smith TJ, Hegedüs L. Graves' disease. *N Engl J Med*. 2016;375:1552-65. doi:10.1056/NEJMra1510030.
2. Haugen BR, Alexander EK, Bible KC, Doherty GM, Mandel SJ, Nikiforov YE, et al. 2015 American Thyroid Association Management Guidelines for Adult Patients with Thyroid Nodules and Differentiated Thyroid Cancer. *Thyroid*. 2016;26:1-133. doi:10.1089/thy.2015.0020.
3. Paschou SA, Vryonidou A, Goulis DG. Thyroid nodules: a guide to assessment, treatment and follow-up. *Maturitas*. 2017;96:1-9. doi:10.1016/j.maturitas.2016.11.002.
4. Neuman D, Kuker R, Vendrame F. Case report Marine-Lenhart syndrome : case report, diagnosis and management. *Case Rep Endocrinol*. 2018;1-4. doi:10.1155/2018/3268010.
5. Joven MH, Anderson R. Marine-Lenhart syndrome. *Endocrine*. 2015;49:570-71. doi:10.1007/s12020-014-0412-x.
6. Kahaly GJ, Bartalena L, Hegedüs L, Leenhardt L, Poppe K, Pearce SH. 2018 European Thyroid Association Guideline for the Management of Graves' Hyperthyroidism. *Eur Thyroid J*. 2018;7:167-86. doi:10.1159/000490384.
7. Damle NA, Mishra R. Identifying Marine - Lenhart syndrome on a 99m Tc - pertechnetate thyroid scan. *Indian J Endocrinol Metab*. 2013;17:366. doi:10.4103/2230-8210.109698.
8. Weetman AP. Radioiodine treatment for benign thyroid diseases. *Clin Endocrinol*. 2007;66:757-64. doi:10.1111/j.1365-2265.2007.02841.x.